

## The Lantern on Top of St.Paul's-Giant Cervical Fibroid

**T Rajeshwari Reddy\*, Pragna Kamjula**

Department of Obstetrics and Gynaecology, Rainbow Hospitals, Hyderabad, India

---

**Citation:** T Rajeshwari Reddy, Pragna Kamjula. The Lanter on Top of St.Paul's-Giant Cervical Fibroid. *Int Jour Gyn Infer.* 2023;1(1):1-5.

**Received Date:** 28 February, 2023; **Accepted Date:** 04 March, 2023; **Published Date:** 06 March, 2023

**\*Corresponding author:** T Rajeshwari Reddy. Department of Obstetrics and Gynaecology, Rainbow Hospitals, Hyderabad, India

**Copyright:** © T Rajeshwari Reddy, Open Access 2023. This article, published in *Int Jour Gyn Infer (IJGI)* (Attribution 4.0 International), as described by <http://creativecommons.org/licenses/by/4.0/>.

---

### ABSTRACT

Fibroids arising from cervix are rare tumours which are accounting for 2% of all fibroids. A central cervical fibroid is usually either interstitial or sub mucous in origin and usually arises from supravaginal portion of the cervix so that it expands the cervix equally in all directions and can displace uterine vessels & ureters. . On laparotomy it can be recognized at once, with uterus on top of tumour like “The Lantern on the top of St. Pauls ”dome mimicking the lantern on the dome of famous of St .Paul’s cathedral of Russia. As they arise from deep pelvis and get impacted, surgery poses difficulties and complications are not uncommon. Here we present a rare case of giant cervical fibroid with broad ligament fibroid with degenerative changes and underwent myomectomy.

**Keywords:** Fibroid; Tumour; Laparotomy

### INTRODUCTION

Leiomyomas are the most common tumours of the uterus. The incidence of leiomyoma is 20% in the reproductive age group, and only 1-2% are found in the cervix<sup>[1]</sup> . Continuous oestrogen secretion especially when uninterrupted by pregnancy and lactation is thought to be the most important risk factor in development of myomata. Cervical fibroids develop in the wall of cervix. They mainly develop in supravaginal part of cervix<sup>[2]</sup>.If cervical fibroid get bigger, it may even push the uterus upwards. Large cervical fibroids are difficult to handle and need an expert hand to operate these cases .The identification of ureters and prevention of injuries to urinary bladder and ureter is important during surgery.

### CASE REPORT

A 30 year old patient underwent medical termination of pregnancy in view of large fibroid uterus . She presented with complaints of retained products of conception associated with fever , pain abdomen, foul smelling discharge and mass per abdomen. Her vitals were recorded as temperature :100F, BP- 130/80 mmhg , Pulse rate – 108/min,per

abdomen findings: mass corresponding to 20 weeks size extending over the umbilical region similar to a 20 weeks pregnancy. On per speculum examination , cervix could not be visualized. On per vaginum examination uterus of 20 -22 weeks, firm to hard in consistency was felt. She underwent MRI PELVIS which showed a large bilobed subserosal fibroid with areas of necrosis and increased vascularity arising from anterior wall of cervix , lower uterine segment and anterior aspect of body of uterus (Figure 2)

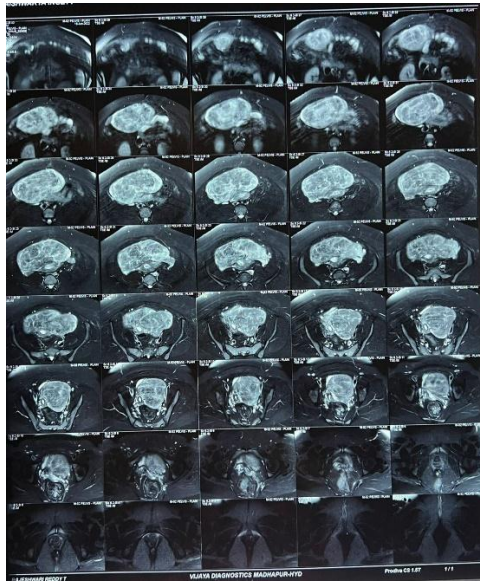


Figure 1

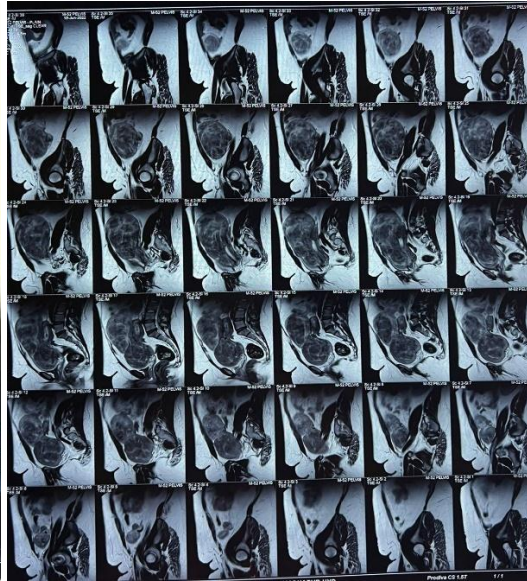

Figure 2

Hence patient was counselled for laparotomy and proceed due to degenerative changes .Intraop we made a subumbilical midline vertical incision , there was a 20x20 cm giant subserosal cervical fibroid extending all over the lower uterine segment and anterior wall of uterus(Figure 3). It appeared to be lantern on dome of st. paul's . Additionally, there was a left broad ligament fibroid of 8x8 cm . (Figure 4)

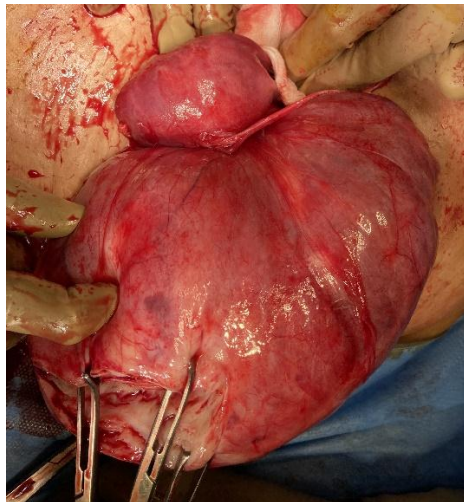


Figure 3

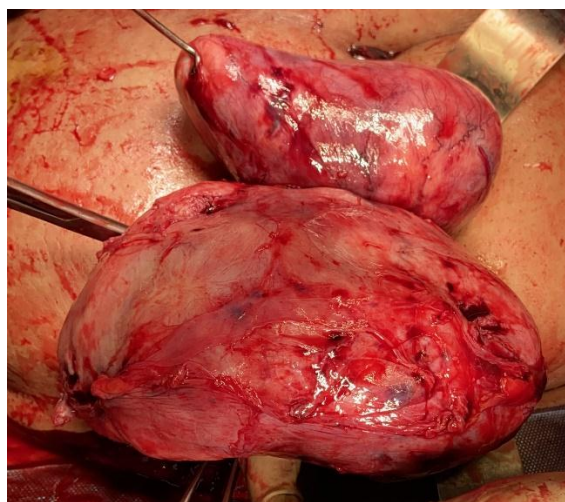


Figure 4



We proceeded with infiltrating vasopressin into the planes and pushed the bladder down by dissecting the uterovesical fold of peritoneum .Leaf of left broad ligament separated .Fibroid dissected and separated skillfully(Figure 5,6) . Patient withstood the procedure well.

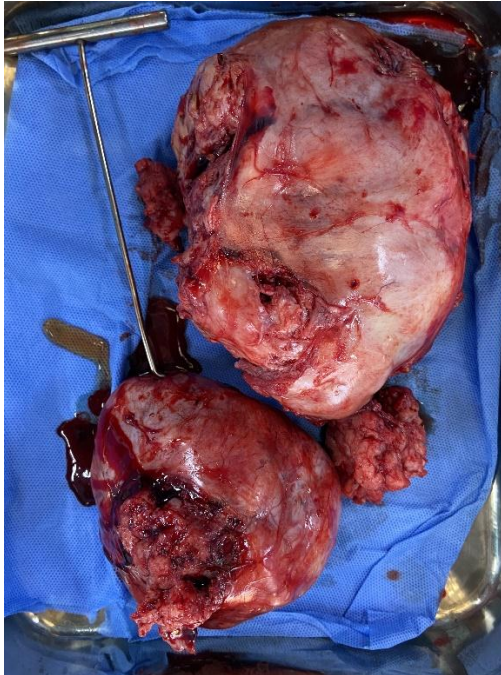

Figure 5

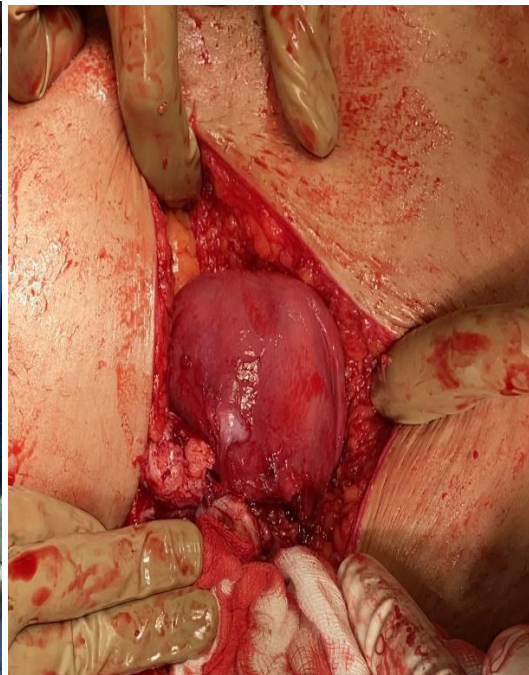


Figure 6

Histopathology revealed as interfacing fascicles and bundles of smooth muscle cells having bland , ovoid nuclei with eosinophilic fibrillary cytoplasm and thin walled blood vessels. Here we discuss about the rarity of cervical fibroid and its presentations and complications(Figure 7)

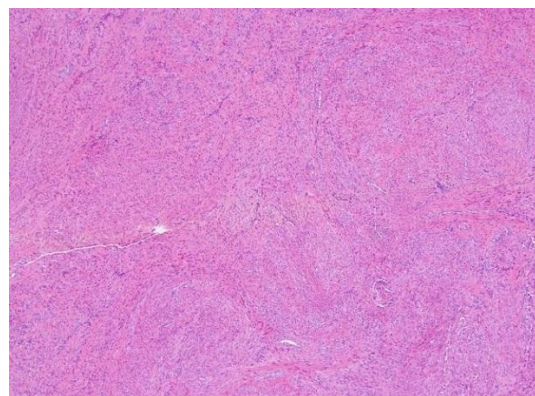


Figure 7

## DISCUSSION

Uterine myomas are the most common indication of hysterectomy. Cervical fibroids with excessive growth are uncommon. Presence of an isolated fibroid in cervix with intact uterus is very rare. They can arise from supra-vaginal or vaginal portion of cervix. Supra-vaginal fibroids can be central surrounding the entire cervical canal and lying centrally in pelvis displacing the ureters superiorly. Pedunculated fibroids arise from endocervical canal or from uterine cavity and protrude through the cervix. Sessile cervical fibroids arise from cervical lips of vaginal portion and are rare<sup>[3]</sup>. Cervical fibroids may be classified as: anterior, posterior, lateral, central and lastly multiple. The symptoms of cervical fibroid depend upon the type of cervical fibroid<sup>[4]</sup>. Anterior fibroid bulges forward and undermines the bladder while posterior fibroid flattens the pouch of Douglas backwards, compressing rectum against sacrum. Lateral cervical fibroid, starting on the side of the cervix burrows out into the broad ligament and expands it.

A cervical fibroid can lead to infertility, urinary retention, urinary frequency when present over the anterior part, constipation when present over the posterior aspect, menstrual abnormalities, dyspareunia, and sometimes post coital bleeding.

Transvaginal ultrasound or transabdominal ultrasound examination may be difficult in cases hence MRI is more often required.

Management of fibroids depends on its size, location and number of fibroids, medical management is preferred only if the patient desires to retain her menstrual and reproductive function and the fibroid is small and not intending surgery. Drugs used are GnRH agonists and antagonists, Mifepristone, Ulipristal (SERMs). Other management options include laparoscopic excision, diathermy/harmonic scalpel loop morcellation and uterine artery embolization. Newer techniques also include MRI guided high frequency ultrasonic ablation of fibroid. They are costly and have disadvantage of recurrence. They are generally suitable for single fibroids <8 cm and not suitable for cervical fibroids.

The treatment of choice for a cervical fibroid is myomectomy or hysterectomy as per the patient criteria.

Coming to the surgical aspect, cervical fibroids relation to the ureter is important. Wherever the ureter and uterine artery may be in relation to the fibroid, they will always be extracapsular<sup>[5]</sup>. The principles of cervical fibroid surgery are enucleation of fibroid followed by hysterectomy to minimize injury to ureters and uterine vessels. The problems anticipated during hysterectomy for cervical fibroid are: 1) uterine vessels- displaced upwards & outwards; 2) Bladder can be pulled up; 3) distortion of normal anatomy of ureters may occur. Therefore, more chances of injury to ureter, bladder and uterine vessels. Anticipation of complications and preventive measures during surgery are the key of successful outcome in large cervical fibroids. To avoid ureteric injury, preoperative stenting, intra-operative delineation of ureters, and dissection inside the fibroid capsule are the best principles.

## CONCLUSION

The abdomen known as the PANDORA 's box which is full of surprises presents cervical fibroids as one of the rare entity amongst the types of fibroid. Sometimes, cervical fibroid with degenerative changes mimics an ovarian tumour and causes a clinical dilemma presenting as lump abdomen. Thorough investigations from imaging modalities like USG, Doppler, CT scan, MRI which gives idea of site, size, vascularity and course of ureter. Good clinical acumen and surgical expertise is required to handle such cases intraoperatively. Proper surgical dissection is required to prevent the injuries to ureter, urinary bladder and the bowel. Dissection and enucleation of cervical fibroid is treatment of choice where fertility preservation is required and it will also help to avoid excessive blood loss, prevent inadvertent injury to ureters or the bladder.

## REFERENCES

1. Bhatla N. Tumours of the corpus uteri. In: Jeffcoates Principles of Gynaecology. 5th ed. London: Arnold Publisher. 2001;470.
2. Tiltman AJ. Leiomyoma of uterine cervix: A study of frequency. Int J Gynaecol. 1998;17:231-234
3. Kumar P, Malhotra N. Tumours of the corpus uteri. In: Jeffcoat's Principles of Gynaecology. 7th Ed.; Jaypee Brothers Medical Publisher (Pvt.) Ltd. New Delhi. 2008;487-516.
4. Buttram VC Jr. Reiter RC. Uterine leiomyomata: etiology, symptomatology, and management. FertilSteril 1981;36:433
5. Swati singh, Priyakshichaudhary. Central cervical fibroid mimicking as chronic uterine inversion, Int ernational Journal of Reproduct contracept Obstet Gynaecol 2013;2(4):687-688.